

Correlation between Clinical Diagnosis, Colonoscopy and Histological Findings of Colon Lesions: A Study of 60 Cases

Manoj Sharma¹, Neil Sharma², M.L. Yadav³, B.P. Nag⁴

¹Assistant Professor ³Professor ⁴Professor and Head, Department of Pathology, Mahatma Gandhi Medical College, Jaipur, Rajasthan 302022, India. ²Assistant Professor, Department of Pathology, Government Medical College, Bharatpur, Rajasthan 321001, India.

Abstract

Background: colonoscopy is the “gold standard” for diagnosis of colonic mucosal disease. Colonoscopy has greater sensitivity than barium enema or CT for colitis, polyps, and cancer. Colonoscopy has the advantage of not only picking up primary cancer but also having the ability to detect synchronous polyps or even multiple carcinomas, which occur in 5% of cases. It tends to be used in patients whose main presenting symptom is bleeding, those with known polyps and those in whom there is doubtful radiology. Ideally, every case should be proven histologically before surgery.

Aims: To establish a correlation between clinical diagnosis, colonoscopy and histological findings of colon lesions.

Materials and Methods: The study was done at Department of Pathology, MGMCH, Jaipur it was a Hospital-based observational study consisting of 60 cases. The findings of clinical diagnosis, colonoscopy and histology were correlated.

Statistical methods: sensitivity, positive predictive value, negative predictive value, and specificity was calculated

Results: Among 60 cases, 41 cases were Nonneoplastic, 15 cases were Neoplastic and 4 cases were classified as biopsy specimen inadequate or unsatisfactory for evaluation. In our study, colonoscopy with biopsy was performed on patients of all age groups, ranging from 2 years to 87 years.

Conclusion: Colonoscopy is a safe procedure and has a high diagnostic yield. The endoscopic evaluation of the large bowel has been greatly expanded by the availability of colonoscopy. A comprehensive histopathological study of the colonoscopy biopsy specimens should be done in constant correlation with the clinical and colonoscopy features.

Keywords: Colonoscopy; Histopathology; Clinical Diagnosis; Polyps; Adenocarcinoma.

Corresponding Author:

Neil Sharma, Assistant Professor
Department of Pathology Government
Medical College, Bharatpur, Rajasthan 321001,
India.

E-mail: neil.nanotech@gmail.com

Received on 18.12.2018,

Accepted on 14.01.2019

How to cite this article:

Manoj Sharma, Neil Sharma, M. L. Yadav et al. Correlation between Clinical Diagnosis, Colonoscopy and Histological Findings of Colon Lesions: A Study of 60 Cases. Indian J Pathol Res Pract. 2019;8(1):75-82

Introduction

Colonoscopy is performed by passing a flexible colonoscope through the anal canal into the rectum and colon. The cecum is reached in >95% of cases, and the terminal ileum can often be examined. Colonoscopy is the "gold standard" for diagnosis of colonic mucosal disease. Colonoscopy has greater sensitivity than barium enema or CT for colitis, polyps, and cancer [1].

The American Cancer Society "Guidelines for the Early Detection of Cancer" recommend, beginning at age 50, both men and women follow one of these testing schedules for screening to find colon polyps and cancer: 1. Flexible sigmoidoscopy every 5 years, or 2. Colonoscopy every 10 years, or 3. Double-contrast barium enema every 5 years, or 4. CT colonography (virtual colonoscopy) every 5 years [2].

Colonoscopy has the advantage of not only picking up primary cancer but also having the ability to detect synchronous polyps or even multiple carcinomas, which occur in 5% of cases. It tends to be used in patients whose main presenting symptom is bleeding, those with known polyps and those in whom there is doubtful radiology. Ideally, every case should be proven histologically before surgery [3].

Disorders of colon account for a large portion of human diseases. Colon is the host to primary neoplasm more than any other organ in the body. Colonic conditions like infections, Idiopathic inflammatory diseases, polyps, motility disorders, and colorectal tumors are important lesions which often require colonic biopsy for their conclusive diagnosis [4].

Mycobacterium tuberculosis (TB) infection is still common in many countries. According to a World Health Organization report, the global annual incidence of TB is estimated to be 9.4 million cases, of which 1.98 million cases are from India [5] and close to 500,000 per year will die of the disease in India [6].

Colonic tuberculosis is rising in general and particularly in patients with AIDS. Colonic tuberculosis can often be diagnosed by histological examination of mucosal biopsies obtained at colonoscopy [7].

Congenital megacolon still commonly known as Hirschsprung's Disease was named after the name of Dr. Harold Hirschsprung, who first gave

the description of the disease. He thought that the colonic dilatation was the cause of the problem, although the actual pathology was in the distal contracted segment. Hirschsprung's Disease has many modes of presentation varying from complete intestinal obstruction to chronic constipation with the classical picture of a pot belly, poor health, and emaciation [8].

The incidence and prevalence of ulcerative colitis in the Indian subcontinent is rising. As it is associated with periods of remissions and relapses, colonic biopsy study is needed to predict relapse for better management and to reduce mortality [9].

Ulcerative colitis is closely related to Crohn's disease. However, intestinal disease in ulcerative colitis is limited to the colon and rectum and extends only into the mucosa and submucosa. In contrast, Crohn's disease, which has also been referred as regional enteritis (because of frequent ileal involvement) may involve any area of the GI tract and is typically transmural [10].

In patients with long-standing inflammatory bowel disease, annual colonoscopy and biopsy can detect dysplastic changes and early cancer [11].

Major diagnostic challenge is to differentiate between intestinal tuberculosis and Crohn's disease, colonoscopic biopsy has a fruitful role in this [12].

Adenocarcinoma of the colon is the most common malignancy of the GI tract and is a major cause of morbidity and mortality worldwide. Colorectal incidence peaks at 60 to 70 years of age and fewer than 20% of cases occur before age 50. Males are affected slightly more often than females [10].

The two most prognostic factors of adenocarcinoma are depth of invasion and the presence of lymph node metastases. These factors were originally recognized by Dukes and Kirklin and form the core of TNM (tumor-nodes-metastasis) classification and staging system [10].

Material & Methods

The study was done at Department of Pathology MGMCH Jaipur from november 2014 to november 2016. It was a Hospital-based observational study consisting of 60 cases. Formalin-fixed specimen of colonoscopic biopsy were received in Pathology Dept. of MGMCH, Jaipur. A brief clinical data was noted from the case records, which includes age and sex of the patient, relevant history if any,

presenting symptoms, colonoscopic findings, and diagnosis. The biopsy specimens so obtained will be fixed in 10% buffered formalin then section of 4-6 micron thickness will be prepared and stained with routine hematoxylin and eosin. Other special stains will be done wherever necessary (eg. Periodic Acid Schiff, Mucicarmine)

Eligibility Criteria

Inclusion criteria: All colonoscopic biopsies and colectomy specimens.

Exclusion criteria: Improper fixation, Autolysed samples, Patients who refuse to give consent.

Stains: Haematoxylin & Eosin stain and Periodic acid Schiff (PAS) were used

Observations

The present study was conducted from October 2013 to September 2015 in the Department of Pathology MGMCH Jaipur. 60 colonoscopic biopsies were studied. Among 60 cases, 41 cases were Nonneoplastic, 15 cases were Neoplastic and 4 cases were classified as biopsy specimen inadequate or unsatisfactory for evaluation.

In our study, colonoscopy with biopsy was performed on patients of all age groups, ranging from 2 years to 87 years.

There was a clustering of cases between 21 to 60 years with maximum cases seen in 21-30 & 41-50 years of age groups each having 14 cases. The least number of cases were seen in the extremes of age group 71-90.

In the present study, there were 39 male patients (65%) and remaining 21 patients were females (35%).

In the present study maximum cases had either chronic diarrhea or bleeding per rectum as a chief complaint or as an associated symptom. The duration of complaints ranged from 1 month to 2 years. Out of these 60 cases, 44 cases were accompanied with pain abdomen and 22 cases were associated with loss weakness. Out of 60 cases, 5 cases had a complaint of constipation.

In the present study of 60 colonoscopic biopsies: 41 (68.3%) cases were diagnosed as non-neoplastic

lesions, 15 (25%) cases were neoplastic, 4 (6%) cases were classified as biopsy specimens unsatisfactory for evaluation, they contained only a few scattered glands lined by colonic epithelial cells.

Table 1: Distribution of all cases

Diagnosis	Clinical	Colonoscopic	Histomorphological
Ca Colon	23	22	15
Polyp	08	09	09
IBD	18	21	16
T.B.	10	06	01
HD	01	01	01
Pouch colon	-	01	-
Non-Specific chronic colitis	-	-	14
Unsatisfactory Biopsy	-	-	04
Total	60	60	60

Table 1 Shows the distribution of all 60 cases with their individual diagnosis clinically, colonoscopically and histologically. These were then compared with other studies done by other researchers.

In the present study of 60 colonoscopic biopsies, 41 cases were diagnosed as non-neoplastic lesions, out of which 14 cases of non-specific chronic colitis, 15 cases of ulcerative colitis 7 cases of juvenile polyp, 2 cases of inflammatory polyp, 1 case of Hirschprung disease, 1 case of Crohn's disease and 1 case of tuberculosis were encountered.

Microscopic features of non-neoplastic lesions

In the present study, 41 cases were non-neoplastic lesions. 14 Cases were of non-specific chronic colitis, characterized by a well-preserved architecture of mucosal glands, normal goblet cells, and predominant lymphoblastic infiltrate in the lamina propria. Some cases also showed lymphoid follicles in the lamina propria. 1 Case of tuberculosis was diagnosed and was characterized by the presence of confluent granulomas with areas of caseation necrosis, aggregation of epithelioid cells, Langhans giant cells and lymphocytic infiltrate. 1 case of Hirschprung disease characterized by mild nerve hypertrophy in the myenteric plexus with the absence of ganglion cells.

In our study, non-neoplastic lesions were seen in patients of all age groups, ranging from 2 years to 87 years. There was a clustering of cases between 0-50 years, with maximum cases seen in 21-30 & 41-50 years.

In the present study, non-neoplastic lesions were

encountered in 28 males (6.3%) and remaining 13 were females (31.7%).

In the present study, patients with IBD, presented mainly between age groups of 21- 50 years.

In the present study, females most commonly presented with IBD.

Microscopy of IBD

15 Cases were diagnosed a Ulcerative colitis mostly showed epithelial necrosis, distortion of glandular pattern, increase in the number of neutrophils, lymphocytes and plasma cells in the lamina propria, crypt abscesses, decrease in the number of goblet cells with the bases of the crypts showing epithelial hyperplasia.

Some cases were characterized by distorted and branched crypts with a villous surface, regenerative hyperplasia of the base of crypts, restoration of the goblet cell population, reduction in the inflammatory cell infiltrate with few polymorphs and/or crypt abscess.

Few cases of ulcerative colitis were characterized by the flat epithelial surface, crypt atrophied and distorted, goblet cell population was normal. The lamina propria showed mild lymphoplasmacytic infiltrate.

There was 1 case of Crohn’s disease in the present study and they were characterized by the presence of small, multiple granulomas, foreign body type giant cells and lymphocytic infiltrate in the mucosa and submucosa.

In the present study, malignant neoplastic lesions were distributed between 21-80 years with clustering of cases seen between 41 -60 years. In the present study, most of them were male patients (60%) and remaining (40%) were female patients.

All malignant cases presented with bleeding per rectum with associated symptoms.

Table 2: Sensitivity and specificity of clinical, colonoscopic and histomorphological diagnosis of carcinoma colon

Ca Colon	Diagnosis		
	Clinical	Colonoscopic	Histomorphological
Positive	23	22	15
Negative	37	38	45
Total	60	60	60

	Diagnosis		
	Clinical	Colonoscopic	Histomorphological
Sensitivity	38.33	36.66	25
Specificity	61.66	63.33	75

As shown table 2, clinical and colonoscopic diagnosis are more sensitive compare to histomorphological diagnosis for carcinoma colon. But histomorphological diagnosis is more specific for carcinoma colon.

Table 3: Sensitivity and specificity of clinical, colonoscopic and histomorphological diagnosis of Juvenile polyp

Juvenile polyp	Diagnosis		
	Clinical	Colonoscopic	Histomorphological
Positive	08	09	07
Negative	52	51	53
Total	60	60	60

	Diagnosis		
	Clinical	Colonoscopic	Histomorphological
Sensitivity	13.33	15	11.66
Specificity	86.66	85	88.33

As shown table 3, clinical and colonoscopic diagnosis are more sensitive compare to histomorphological diagnosis for colorectal polyps. But histomorphological diagnosis is more specific for colorectal polyps.

Table 4: Sensitivity and specificity of clinical, colonoscopic and histomorphological diagnosis of Inflammatory Bowel Disease

IBD	Diagnosis		
	Clinical	Colonoscopic	Histomorphological
Positive	18	21	16
Negative	42	39	44
Total	60	60	60

	Diagnosis		
	Clinical	Colonoscopic	Histomorphological
Sensitivity	30	35	26.66
Specificity	70	65	73.33

As shown Table 4, clinical and colonoscopic diagnoses are more sensitive compared to histomorphological diagnosis IBD. But histomorphological diagnosis is more specific for IBD.

Table 5 Sensitivity and specificity of clinical, colonoscopic and histomorphological diagnosis of Tuberculosis.

TB	Diagnosis		
	Clinical	Colonoscopic	Histomorphological
Positive	10	06	01
Negative	50	54	59
Total	60	60	60

	Diagnosis		
	Clinical	Colonoscopic	Histomorphological
Sensitivity	16.66	10	1.66
Specificity	83.33	90	98.33

As shown Table 5, clinical and colonoscopic diagnosis are more sensitive compared to histomorphological diagnosis tuberculosis. But histomorphological diagnosis is more specific for tuberculosis.

Table 6: Sensitivity and specificity of clinical, colonoscopic and histomorphological diagnosis of Non-specific chronic colitis

Non-specific chronic colitis	Diagnosis		
	Clinical	Colonoscopic	Histomorphological
Positive	0	0	14
Negative	60	60	46
Total	60	60	60

Histomorphological diagnosis	
Sensitivity	23.33
Specificity	76.66

As shown in table 6, clinically it was not diagnosed as chronic colitis but was reported on histopathology. The specificity of histomorphological diagnosis for non-specific chronic colitis is 76.6%.

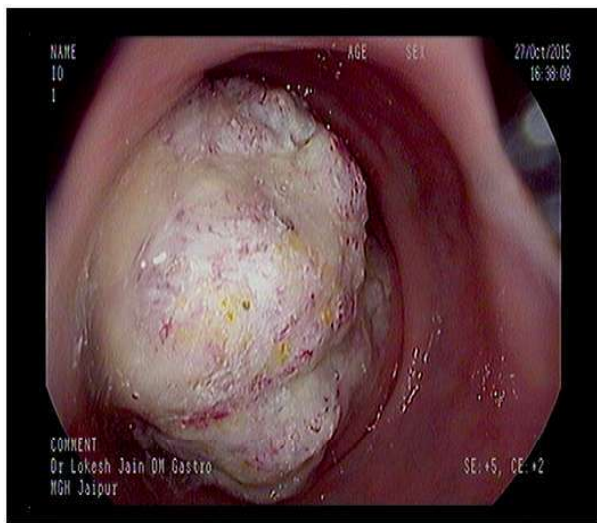


Fig. 1: Colonoscopic view of cancerous growth in colon

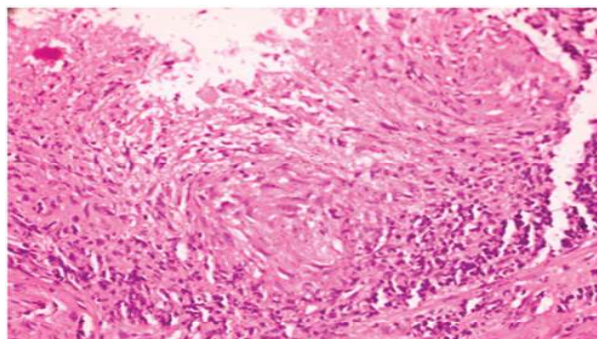


Fig. 3: Tuberculosis, Granuloma (HPE H&E 40X)

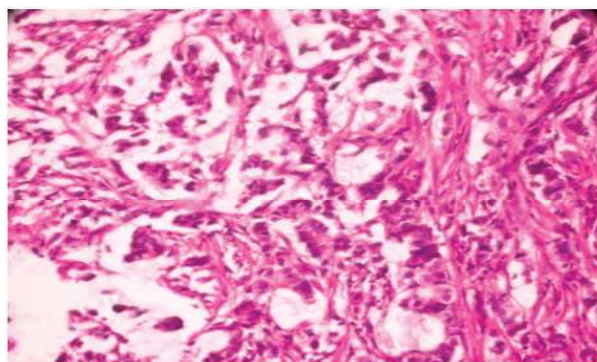


Fig. 4: Poorly differentiated adenocarcinoma colon (HPE H&E 10X)

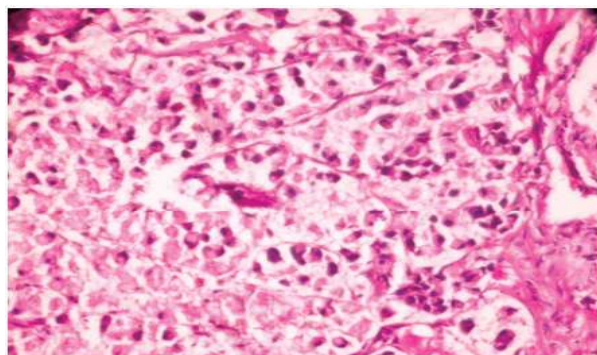


Fig. 5: signet ring cell adenocarcinoma colon (HPE H&E 40X)

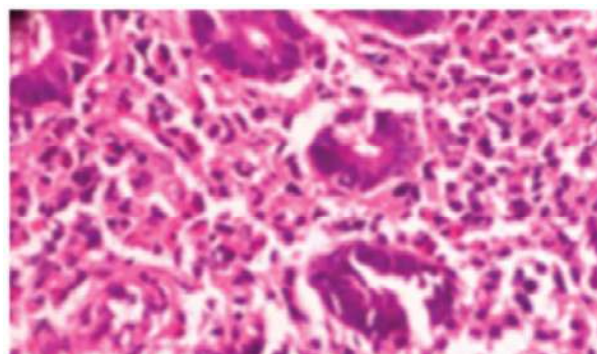


Fig. 2: Ulcerative colitis, Crypt Abscess (HPE H&E, 40X)

Discussion

Colonic conditions like infections, IBD, polyps, motility disorders, and colorectal tumors are important lesions which often require colonic biopsy for their conclusive diagnosis. Lower endoscopic evaluation is established as the diagnostic procedure of choice in the setting of diarrhea and lower GI bleed.

A study population of 60 were considered for colonoscopic biopsies from patients presenting with chronic diarrhea/bleeding per rectum as

either a chief complaint or associated symptom were studied. Out of these 39 were males and 21 were females.

Out of these 60 cases, 48 cases presented with bleeding per rectum, 26 cases were accompanied with chronic diarrhea, 44 cases were associated with pain abdomen and 30 cases were associated with weakness.

In our study clustering of cases between 21 to 50 years with maximum cases seen in 21-30 (23.3%) & 41 to 50 (23.3%) years of age groups each having 14 cases This finding corresponds with study series of Hassan Abdulla Alaqli 111, which showed clustering of cases between 21-60years with maximum cases seen in 21-30years (24.4%) and 31-40 years (23.2%).

In our study, out of 60 cases, 41 (68.3%) cases were non-neoplastic, 15 (25%) cases were neoplastic and 4 (6.6%) cases were unsatisfactory.

This finding similar with the study series of Azar Qayyam et al where non-neoplastic lesions were maximum cases, followed by neoplastic lesions and unsatisfactory biopsy. In the present study, of the 41 cases diagnosed as non-neoplastic lesions, 14 (34.1%) cases comprised of chronic colitis, 9 (22%) cases were polyps, 16 (39%) inflammatory bowel disease. Similar findings were encountered with the study series of A. Quyyam et al and Rangaswami et al where chronic colitis were maximum cases.

Adenocarcinoma is the commonest malignant tumor of the colon and rectum. Colorectal carcinoma becomes more frequent with increasing age and in the present study the average age at the time of diagnosis being 51 years. It is more common in males (60%). These findings were in accordance with studies done by Thomas FI et al. In the present study, 15 cases of malignancy were diagnosed as adenocarcinoma. Majority of cases were males comprising of 9 cases and 6 were females. Most of the cases belonged to 4th and the 5th decade that are 5 cases and 4 cases (total of 9 cases). The signet ring adenocarcinomas were seen in between 20-70 years.

All 15 cases were presented with bleeding per rectum with associated symptoms.

In the present study, of the 11 cases of adenocarcinomas, 3 (27.7%) were well differentiated, 5 (45.5%) were moderately differentiated, 3 (27.7%) were poorly differentiated and 4 cases were signet ring adenocarcinoma, corresponded to studies conducted by Janasson L et al. and Rangaswami

et al showed maximum cases of moderately differentiated adenocarcinoma.

Table 7: Showing the comparison of sensitivity and specificity of colonoscopy for carcinoma colon

Study	Sensitivity	Specificity
Allameh Z et al. (2011)13	90	99
Emanuele Neri et al. (2002)14	56	92
Present study	36.7	63.3

As shown in table 7, all studies showing that specificity of colonoscopy is more compare to sensitivity for carcinoma colon.

Table 8: Showing a comparison of sensitivity and specificity of histomorphology for carcinoma colon

Study	Sensitivity	Specificity
Alexander J et al. (2001)15	14-38%	87-99%
Present study	25%	75%

As shown in table 8, both studies showing more specificity of histomorphology for carcinoma colon.

Table 9: Showing a comparison of specificity of colonoscopy for colorectal polyps

Study	Specificity
Naom Shussman et al. (2002)16	90%
Schachschal et al. (2014)17	73%
Present study	85%

As shown in table 9, the present study is comparable with Naom Shussman et al and Schachschal et al., showing specificity 85% of colonoscopy for colorectal polyps which are nearby other two studies.

Table 10: Showing a comparison of sensitivity and specificity of colonoscopy for IBD

Study	Sensitivity	Specificity
Shabana et al. (2007)18	83%	44%
Konuma Y. et al. (1995)19	94%	95%
Present study	35%	65%

As shown in table 10, in the present study sensitivity and specificity are 35% and 65% which can be compared with Konuma Y. et al. study which also showing more specificity of colonoscopy for IBD.

Table 11: Showing a comparison of sensitivity and specificity of histomorphology for IBD

Study	Sensitivity	Specificity
Yuzuru et al (1995)19	94	95
Present study	26.6	73.3

As shown table 11, in both studies, the specificity more compare to the sensitivity of histomorphology for IBD.

Conclusion

Colonoscopy is a safe procedure and has a high diagnostic yield. The endoscopic evaluation of the large bowel has been greatly expanded by the availability of colonoscopy. Whereas inspection and occasional biopsy had formerly been limited to the distal sigmoid region and rectum, examination of the entire colon is now possible in most cases. The age distribution of patient who underwent colonoscopy biopsy range from a 2 years child to an 87-year-old man proving that it is a safe procedure. A variety of both non-neoplastic and neoplastic lesions were reported in the present study across a wide age distribution and findings correlated well with that of similar studies. Much difficulty was encountered incorrect interpretation because of the small size of the biopsy specimens received, and many times because of the biopsy is not representative of the lesions. A greater awareness of the disease and understanding of pathogenesis on the part of the pathologist was also felt to be necessary for a better-improved diagnosis.

Histopathological diagnosis correlated well with the colonoscopy diagnosis offered.

Thus colonoscopic biopsy is an important tool in the diagnosis of the large bowel diseases.

A comprehensive histopathological study of the colonoscopy biopsy specimens should be done in constant correlation with the clinical and colonoscopy features. Colonoscopy with biopsy may be used for follow up of inflammatory diseases like ulcerative colitis and Crohn's disease, to define epithelial dysplasia in case of chronic colitis and that help in the early detection of carcinoma in such cases. Colonoscopic screening can detect advanced colonic neoplasms in asymptomatic adults.

Hence colonoscopy biopsy has increased the role of the pathologist in the diagnosis and management of diseases of the large bowel while and scoring a constant correlation with clinicians, but a correct interpretation still chooses to be an exciting diagnostic challenge for most pathologist because of the small size of specimens.

References

1. Kasper DL, Braunwald E, Fauci AS, Hauser SL, Longo DL, Larry Jameson J. Harrison's Manual of Medicine: 16th Edition. McGraw Hill Professional; 2005.p.1016.
2. Smith RA, Cokkinides V, Eyre HJ. American Cancer Society guidelines for the early detection of cancer, 2006. CA Cancer J Clin. 2006 Jan;56(1):11-25; quiz 49-50.
3. Mann CV, Bailey H. Bailey & Love's Short Practice of Surgery. Chapman & Hall Medical; 1995.p.1041.
4. Qayyum A, Sawan AS. Profile of colonic biopsies in King Abdul Aziz University Hospital, Jeddah. J Pak Med Assoc. 2009 Sep;59(9):608-11.
5. World Health Organization. Global Tuberculosis Control: Epidemiology, Strategy, Financing : WHO Report 2009. World Health Organization; 2009.p.303
6. Khatri GR, Frieden TR. Controlling tuberculosis in India. N Engl J Med. 2002 Oct 31;347(18):1420-5.
7. Shah S, Thomas V, Mathan M, Chacko A, Chandy G, Ramakrishna BS, et al. Colonoscopic study of 50 patients with colonic tuberculosis. Gut. 1992 Mar;33(3):347-51.
8. Khan AR, Vujanic GM, Huddart S. The constipated child: how likely is Hirschsprung's disease? Pediatr Surg Int. 2003 Aug;19(6):439-42.
9. Azad S, Sood N, Sood A. Biological and histological parameters as predictors of relapse in ulcerative colitis: a prospective study. Saudi J Gastroenterol. 2011 May;17(3):194-8.
10. Kumar V, Abbas AK, Aster JC. Robbins & Cotran Pathologic Basis of Disease. Elsevier Health Sciences; 2014.p.1472.
11. Lynch DA, Lobo AJ, Sobala GM, Dixon MF, Axon AT. Failure of colonoscopic surveillance in ulcerative colitis. Gut. 1993 Aug;34(8):1075-80.
12. Kirsch R, Pentecost M, Hall P de M, Epstein DP, Watermeyer G, Friederich PW. Role of colonoscopic biopsy in distinguishing between Crohn's disease and intestinal tuberculosis. J Clin Pathol. 2006 Aug;59(8):840-4.
13. Allameh Z, Davari M, Emami MH. Sensitivity and specificity of colorectal cancer mass screening methods: a systematic review of the literature. Iranian Journal of Cancer [Internet]. 2011; Available from:<http://journals.sbmu.ac.ir/cp/article/view/2395>
14. Ibrahim KO, Anjorin AS, Afolayan AE, Badmos KB. Morphology of colorectal carcinoma among Nigerians: a 30-year review. Niger J Clin Pract. 2011 Oct;14(4):432-5.
15. Alexander J, Watanabe T, Wu TT, Rashid A, Li S, Hamilton SR. Histopathological identification of colon cancer with microsatellite instability. Am J Pathol. 2001 Feb;158(2):527-35.
16. American Institute for Cancer Research. Colon Cancer Prevention: Dietary Modulation of Cellular

- and Molecular Mechanisms. Springer Science & Business Media; 2000.p.165.
17. Schachschal G, Mayr M, Treszl A, Balzer K, Wegscheider K, Aschenbeck J, et al. Endoscopic versus histological characterisation of polyps during screening colonoscopy. *Gut*. 2014 Mar;63(3):458-65.
 18. Pasha SF, Leighton JA. Novel Techniques in the Diagnosis of Inflammatory Bowel Disease. In: Cohen RD, editor. *Inflammatory Bowel Disease: Diagnosis and Therapeutics*. Totowa, NJ: Humana Press; 2011.pp.231-53.
 19. Konuma Y, Tanaka M, Saito H, Munakata A, Yoshida Y. A study of the histological criteria for ulcerative colitis: retrospective evaluation of multiple colonic biopsies. *J Gastroenterol*. 1995 Apr;30(2):189-94.
-